




# Suzanne Caudry, PhD, DDS, MSc [Perio] and the Caudry Education Centre

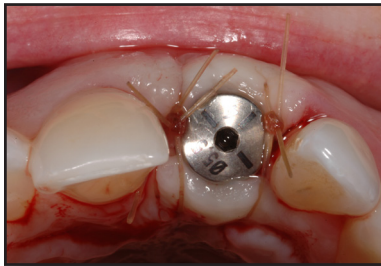


Newsletter Volume 12

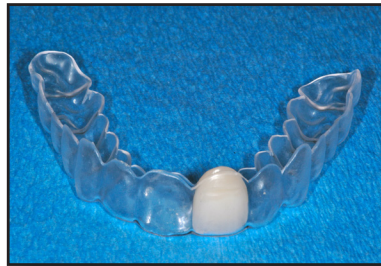Winter 2014

## TEMPORIZATION: POST-SURGICAL PLANNING

One of the most hotly debated areas in Implant Dentistry relates to immediate placement and immediate temporization. Since first lecturing on this topic more than a decade ago, I find that our scientific community is still divided on whether treatment risks outweigh potential rewards. We have yet to reach a definitive consensus.



1a. Immediate implant with HA.

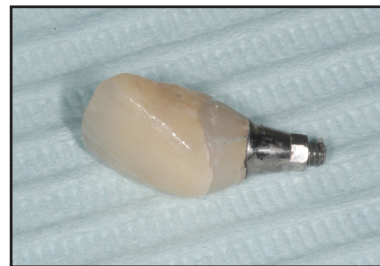

1b. Essix for temporization of 1a.

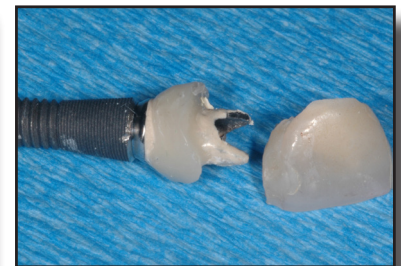It is critical that post-surgical treatment planning for temporization of an immediate implant be discussed with the patient *prior* to surgery. Patient occlusion, parafunction and compliance are also significant risk factors that must be thoroughly investigated and addressed prior to commencing treatment.

Even an appliance as seemingly straightforward as an **Essix-type of retainer** (Photo 1a, 1b) has the potential for risk. A question often overlooked: Will the patient tolerate this temporary solution? If so, will they be compliant regarding its limited functionality?

**Temporary abutments and temporary crowns** are the preferred method of temporization for immediate implants as they contribute to successful aesthetics in the short and long term (2). The risk factors are high and often relate directly to the patient. Does the patient fully understand the functional limitations of a temporary crown and abutment? Fracture of the temporary crown will be a nuisance but catastrophic failure of the implant is a much greater concern. (Refer to the Summer 2014 Newsletter for a guideline to replicating natural teeth with cement-retained temporaries).



2. Temporary custom abutment and crown (lab fabricated).

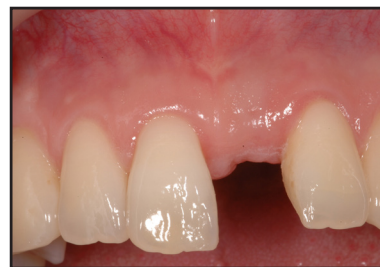

3. Immediate implant with immediate temporization destabilized shortly after surgery when the patient bit into an apple.

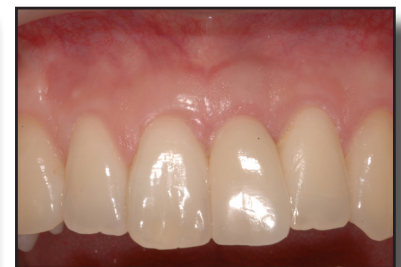Although this patient was fully informed and signed a waiver regarding the limits of functionality of the temporary, he bit into an apple shortly after surgery (3).

In the Fall 2014 Newsletter ([www.drcaudry.ca](http://www.drcaudry.ca); "Continuing Education"; "Newsletters") we looked at a case with significant bone resorption at 3 months post-implant placement.

Since the buccal bone fully resorbed, the implant was removed and the site was reconstructed (4a). After healing, another implant was subsequently placed. The final result is shown (4b).



4a. Healed site after failed implant was removed and site was reconstructed (Refer to Figs. 5 and 6 from Fall 2014 Newsletter).



4b. Replacement implant and final restoration.

In this instance, the risk of placing an immediate far exceeded the reward due to the complications that arose.



# The Caudry Education Centre - 2014



## Continuing Education

### Recent Publication Announcement

ORAL HEALTH JOURNAL, PROSTHODONTIC EDITION, November 2014 (pg. 50-56): "Temporizing Immediate Implants: Creating the Foundation for Long-term Success " by Dr. Suzanne Caudry.

### Innovative Continuing Education

> **Mentorship Program:** By popular request, I will be launching a new small-group mentorship program, beginning February 2015 (groups of 5 participants, max). This program is for restorative dentists looking to expand their knowledge base. It will involve group case discussion from diagnosis through to follow-up protocols. Contact us if you are interested in participating.

> **Blog:** [www.drcaudry.ca](http://www.drcaudry.ca): Visit our Blog at [www.drcaudry.ca](http://www.drcaudry.ca) and tell us your thoughts on our 45-year-old healthy, non-smoking, class 1 occlusion patient with a crown on tooth 21 that "keeps falling off". What would you do?

### 2015 Study Clubs

> **Thursday, February 26, 2015:** Decision-making criteria for immediate implant placement. This topic is still one of the most debated in dental implant circles. We'll review recent research and discuss whether anything has really changed.

> **Thursday, April 30, 2015:** Esthetics for immediates. The Summer 2014 Newsletter presented a cement-retained approach to allow for proper implant positioning. We'll discuss other esthetic options and the pros and cons of each.

> **Thursday, October 8, 2015:** Complications with immediate implants. Catastrophic failure vs. nuisance failures - which is worse? How to deal with soft tissue and hard tissue trauma and how to make the most difficult decisions.

*Space is limited. CE points and dinner provided. Please call to reserve your spot: 416-928-3444.*



## AAID (American Academy of Implant Dentistry)

On Friday, November 7, 2014 I will be attending the AAID meeting and am honoured to have been asked to lecture at their meeting once again. My combination lecture and hands-on session will be regarding "Implant Site Development - Creating the Foundation for Success". Check my website and LinkedIn after that date for an overview of the meeting.



## Save-the-date

Plan to join us on **Thursday, January 15, 2015** when I will discuss recent advancements in implant systems and how these advancements can improve currently available treatment options. Details to follow; please call if you wish to be on the preliminary list of attendees.



**Suzanne Caudry, PhD, DDS, MSc [Perio]**  
1235 Bay Street, Suite 602 • Toronto, Ontario M5R 3K4  
Telephone: 416-928-3444 • Fax: 416-972-0640  
[scaudry@drcaudry.ca](mailto:scaudry@drcaudry.ca) • [www.drcaudry.ca](http://www.drcaudry.ca)