



Suzanne Caudry, PhD, DDS, MSc [Perio] and the Caudry Training Centre

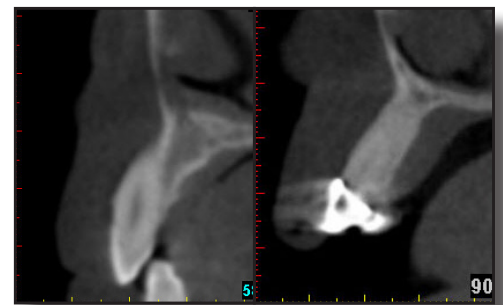

BIOLOGY MAY WIN - REVISITING IMMEDIATE IMPLANTS - Part 1

Immediate implant placement continues to be a heavily debated topic and one that I have lectured on since 2005. The research has changed yet the most important question of all still remains: are the risks worth the rewards? Even the most meticulous treatment planning can be outsmarted by anatomy and biology. Anatomical issues such as bone defects and angulation can often be diagnosed pre-surgically but biological issues can be more elusive.

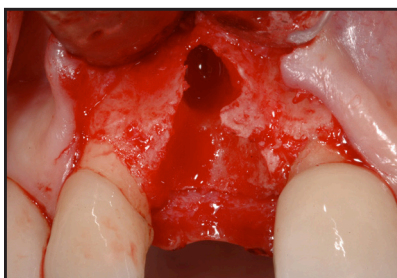MINIMIZING SURPRISES: PRE-SURGICAL PLANNING

A CT scan is the best implant treatment planning tool available. CT #1 shows that there is an angulation problem, a buccal concavity and lack of bone volume. However, a CT does not always provide accurate information regarding bone thickness, or about defects such as dehiscences and fenestrations. The presence of socket walls is a critical component for successful immediate implant placement yet we will not always be sure of the status of the socket walls until after the tooth has been extracted. In CT#2 the angulation is acceptable but we can see that the natural tooth extends from the buccal to the palatal plate. After extraction, the integrity of the socket walls is questionable. Here, biology may win.

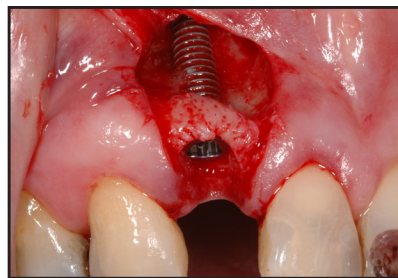


CT #1

CT #2

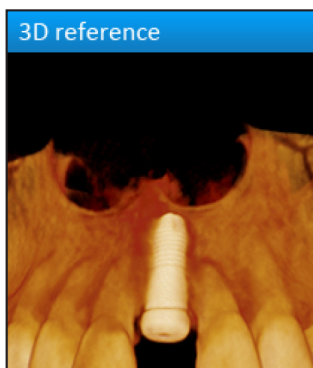


3. Dehiscence

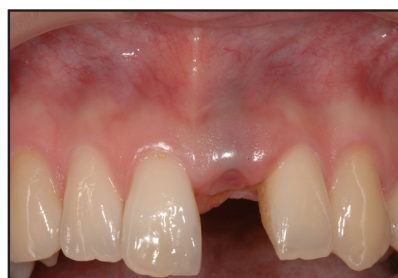

4. Failed Implant

A flapless technique is preferred for immediate implants. Sounding bone alone would rule out a dehiscence (3) but it would not rule out a fenestration such as the one that likely existed before the implant was placed (4). Probing upon extraction will disclose whether socket walls exist but not the thickness of those walls. Yet again, biology may win.



5. CT: 3 months post-implant




6. Note grey coloration

The volume of bone in this case seemed sufficient at the time of immediate implant placement - however three months later, there had been significant resorption of the buccal plate (5 & 6). The Winter issue of this Newsletter will review the case in greater detail.



The Caudry Education Centre - 2014



What's Happening

Upcoming Study Clubs

> **Thursday, September 18, 2014:** Our final 2014 study club meeting will review treatment of implant complications. Please confirm your spot since space is limited.

> **Thursday, February 26, 2015:** Decision making criteria for immediate implant placement. This topic is still one of the most debated in dental implant circles. We'll review recent research and discuss whether anything has really changed.

> **Thursday, April 30, 2015:** Esthetics for immediates. The Summer 2014 Newsletter presented a cement retained approach to allow for proper implant positioning. We'll discuss other aesthetic options and the pros and cons of each.

> **Thursday, October 8, 2015:** Complications with immediate implants. Catastrophic failure vs nuisance failures - which is worse? How to deal with soft tissue and hard tissue trauma and how to make the most difficult decisions. The Winter issue of this newsletter will cover the topic.

Space is limited. CE points and dinner provided. Please call to reserve your spot: 416-928-3444.

International Speaking Engagement

> **Friday, November 7, 2014:** Dr. Caudry has been asked to lecture again at the AAID [American Academy of Implant Dentistry] meeting in Florida. She last presented for them at their 10th year anniversary conference in October 2011.



Innovative Continuing Education

For many years I have been searching for ways of expanding continuing education beyond the walls of a lecture room. This fall I will be launching a BLOG through my website: www.drcaudry.ca. Every month a new case will be posted and readers will be asked to post comments. I am hoping for the same type of lively discussions that we have during the study club meetings!



Suzanne Caudry, PhD, DDS, MSc [Perio]
1235 Bay Street, Suite 602 • Toronto, Ontario M5R 3K4
Telephone: 416-928-3444 • Fax: 416-972-0640
scaudry@drcaudry.ca • www.drcaudry.ca